

# ACE newsletter



News of how your support is helping animals in Luxor

## As a charity we still continue to struggle financially

Each month our savings are depleted further. Our monthly costs far exceed our regular monthly income from donations so we are asking supporters from the bottom our hearts to set up a regular gift. Even just £3 per month becomes much more when people join together to support a great cause that they believe in. Thank you all so much for your help in making the world a happier place for animals.

Every day at ACE there are many happy and sad moments. There is joy when the inpatients are ready to go home and can continue with their lives.

The foal in this picture is a particularly sad case as the hopes of his young owner were shattered when his mother was spooked and she landed on her foal's leg. Both the long and short pastern bones were crushed.

## A sad story

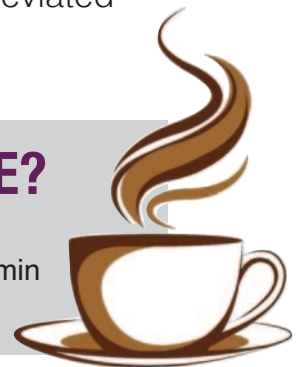

After the X-rays it was clear that this was the end of the road for this dear fellow. After the young man made a call to his family it was agreed that they would give us permission to end this young equine's life.

We are very grateful that they came to us quickly so that his suffering from this most painful break could be alleviated straight away.

## CAN YOU DONATE THE PRICE OF A CUPPA TO ACE?

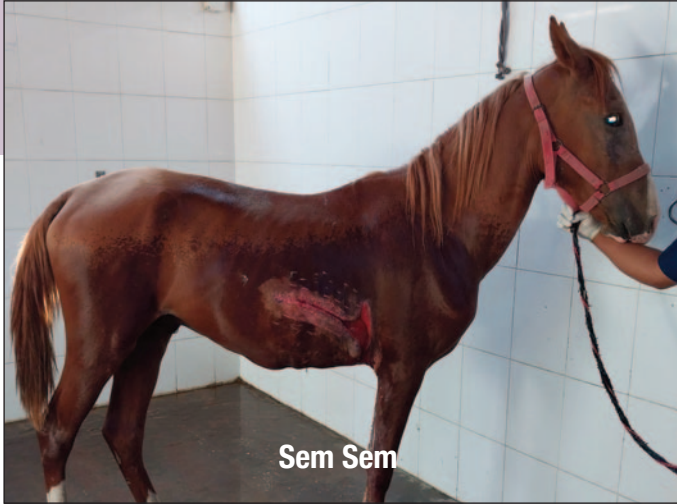The average price of a cuppa is around £2.60 / \$3.14 / €2.93. Go on... Give it a Go! Your swap will help provide a free wormer to a dog or donkey, or a much needed vitamin injection. Just think how happy and grateful the animals will be.



**We are so grateful to you our loyal supporters for enabling us to be here in every emergency situation.**

# Over The Stable Door

Some of our inpatients that have received care thanks to...  
**you** our supporters



Sem Sem is a riding horse that was hit by a car whilst his owner was out exercising him. Unfortunately his prognosis is guarded as the wound is very deep and the area that is sutured is not healing together very well. Our team will do their very best for this unfortunate soul.



Bella arrived with a nasty wound on her neck following yet another road traffic accident. Her wound had to be debrided and treated daily to prevent infection. Bella is a very quiet and kind natured mare and has been so gentle whilst being treated.



We named this cute long eared lad Tuk Tuk after the vehicle that sliced into his flank during a road traffic accident. At the time of writing this newsletter he had just arrived, brought in by his caring owner who knew he really needed immediate vet care.



Blue is a boisterous lad who has been quite a grumpy patient during his hospitalisation with us. The good news is that his wound is improving but we are currently trying to reduce the amount of 'proud flesh', or granulation tissue, that has formed as this can interfere with the growth of new skin.

*We value your support and would like to keep you informed about our*  
If you do NOT wish to receive further information from ACE, please



[www.facebook.com/aceegyptfan](https://www.facebook.com/aceegyptfan)



[twitter.com/aceegypt](https://twitter.com/aceegypt)




[www.linkedin.com/company/ace?trk=company\\_name](https://www.linkedin.com/company/ace?trk=company_name)





Ruby

Ruby is a very skittish and nervous young filly who arrived with multiple wounds following an accident. She is slowly beginning to trust our team when they handle and treat her.



Sammy

Sammy has been admitted for treatment for the many sarcoids on his forelegs and around his mouth. Unfortunately he has been assisting in spreading them to his muzzle by nibbling on them. Sarcoids are a very common skin tumour that affects both horses and donkeys. Our vets treat these with their own cream that they have developed here and have great success in treating these nasty growths.

## Great owner



This is Beshoye and his cute dog Lulu who visited our small animal clinic recently. It is heart-warming to see that more people are seeing dogs as companions rather than just guard dogs. Lulu has been vaccinated and is being taken very good care of.

A dog is for life....

## Spay and Neuter funding

Here in Luxor we are very proud of the fact that so many local people are making the important decision to spay or neuter their cats and dogs. At our charity hospital we provide this free of charge for the locals' pets, but the cost of the anaesthetic, painkillers and antibiotics is increasing dramatically.

Please help us to continue to provide this service as, unfortunately, too many new born puppies and kittens are unwanted and just discarded in the streets. Together we can help to prevent this from happening to these poor creatures.

**Together we can help to prevent this from happening so often.**

## Irresponsible tourism

During the summer months tourism has increased much more than in recent years here in Luxor. Whilst that is great for the local people, we are so disheartened to see so many irresponsible tourists taking a city tour in the heat of the day via horse and carriage. With daily temperatures exceeding 40 degrees, we are appalled to see people choosing to do this activity in the hellish afternoon heat when they can opt for cooler evenings.

**Please enjoy your holiday but not at the expense of animal welfare.**

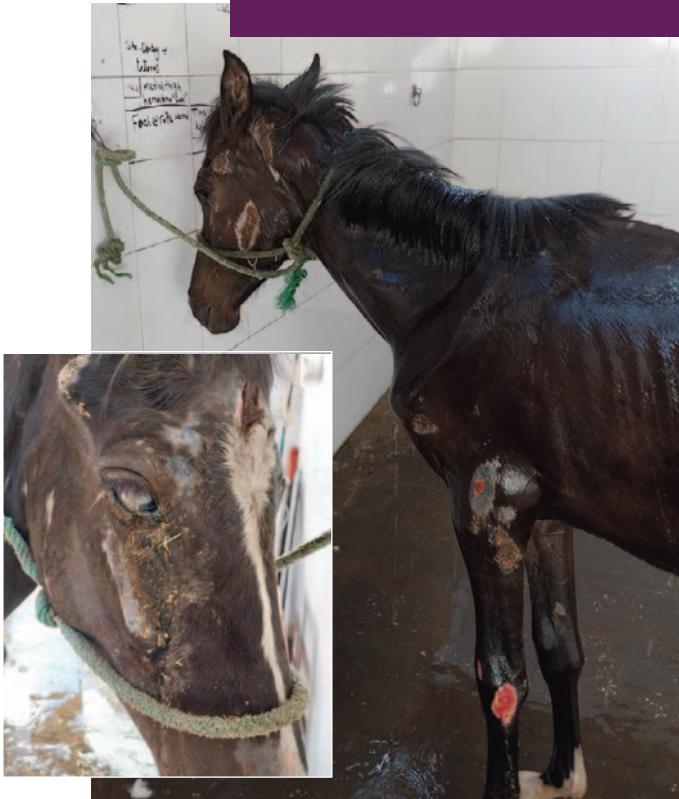*animal welfare work and fundraising activities either by post or via email.*  
email us at [supporter@ace-egypt.org.uk](mailto:supporter@ace-egypt.org.uk) or write to us at the address below.

**Animal Care in Egypt, 10 Stretham Road, Wicken, Cambridgeshire CB7 5XH**

Registered Charity no. 1082679 Registered in Egypt Society Luxor# 2/2015



**Before...**



## Myositis foal

This poor young lad had myositis which is a condition caused by a deficiency of selenium and vitamin E in the foal's diet. This caused muscle atrophy so he had been struggling to stand up, hence the sores on his body. He also had a nasty rope burn on his hind leg which was the least of his problems. You can see in one of the photos that he damaged his face whilst on the floor and caused a huge corneal ulcer too.

He had a guarded prognosis but with your help his condition vastly improved as seen in the 'after' photos.

## Feline Herpes Virus

**Sometimes, we have to say goodbye to a little soul without having any other choice.**

This kitten was brought to us less than 40 days old. We had no option but to euthanise her. She was suffering from a well-established respiratory infection called Feline Herpes Virus. This virus is extremely contagious and, unfortunately, quite common here as most people do not vaccinate their pets. The symptoms of FVR involve the nose, throat and eyes. They include sneezing, nasal congestion, conjunctivitis, excessive blinking, squinting and watery to thick and purulent discharge. This poor babe also had an acute upper respiratory infection.

**Rest in peace lovely angel.**

**After...**



**FOR MORE INFORMATION** or for a fundraising pack (most information can be found on our website) please contact Helen on: +44(0)79 7986 5352 or: [helen@ace-egypt.org.uk](mailto:helen@ace-egypt.org.uk)

**DONATE** though our website, using PayPal or Credit/debit card. Or you can post any donations to: Animal Care in Egypt, 10 Stretham Road, Wicken, Cambridge, CB7 5XH.



Visit our website [www.ace-egypt.org.uk](http://www.ace-egypt.org.uk)